

Cervical Cancer and Multiple Sclerosis: What is the urodynamic profile? A clinical case study with literature review

K. DAAIFI *, S. SKALLI, I. EL AZHARY, L. ESSOUAYNI and S. KARKOURI

Department of Physical and Rehabilitation Medecine, Ibn Sina University Hospital of Rabat, Faculty of Medicine and Pharmacy of Rabat, Morocco.

World Journal of Advanced Research and Reviews, 2025, 27(03), 080-085

Publication history: Received on 25 July 2025; revised on 29 August 2025; accepted on 02 September 2025

Article DOI: <https://doi.org/10.30574/wjarr.2025.27.3.3119>

Abstract

Introduction: Bladder and sphincter disorders (BSDs) affect nearly 90% of patients with multiple sclerosis (MS) at some point in their disease. Surgeries for pelvic cancers such as radical hysterectomy and radiation therapy for cervical cancer (CC) are another common cause of urinary complications due to neurogenic or damage to the tissues. The following report describes a representative patient who suffered the compounding effects of MS and conditions of treating cervical cancer on her urodynamic history.

Observation: A 30-year-old female patient, who has been monitored for MS since 2018 and who has been treated with Rituximab, developed CC that was treated in 2022 with surgical removal of the uterus and cervix (extended hysterectomy) and radiation therapy to her pelvis. At that time, she presented with urinary symptoms, including dysuria, the need for abdominal thrusts, and incomplete emptying. The report evaluating her pattern of voiding completed specified that she was doing so at low volumes and not leaking with voiding. An ultrasound evaluation of her kidney prompted an assessment of mild bilateral ureterohydronephrosis. Urodynamic assessment in this patient acquired the following information: bladder hypoesthesia with detrusor hypocontractility and 550 mL post-void residual urine. The patient had a stable detrusor with mild involuntary contraction, adequate compliance, and no evidence of detrusor-sphincter dyssynergia.

Discussion: Involvement of neurovegetative lesions by pelvic surgery may include alteration of the sympathetic and parasympathetic pathways responsible for bladder control, thus producing voiding disorders. Interpretation of bladder radiotherapy as an exacerbation occurs through continued and progressive fibrosis and ischemia of the bladder wall. Multiple sclerosis course can incite a wide variety of symptoms, as we learnt here from this patient that included detrusor hypoactivity along with the other symptoms that she developed, due to a diagnosis of MS and also due to treatment of cervical cancer.

Conclusion: This case highlights the complexity of the interplay between neurological pathology and urogynecological sequelae. Urodynamic assessment is critical for personalized management.

Keywords: Multiple sclerosis; Cervical cancer; Bladder-sphincter disorders; Urodynamics; Detrusor hypocontractility; Hysterectomy; Pelvic radiotherapy

1. Introduction

Multiple sclerosis (MS) is an autoimmune disease of the central nervous frequently associated with urinary tract dysfunction, affecting up to 96 % of patients within the first 10 years of disease progression (1).

* Corresponding author: K. DAAIFI

Cervical cancer is the fourth most common cancer among women worldwide. In Africa, it ranks second in incidence and mortality, with 117,316 new cases and 76,745 deaths (2,3). Early-stage disease is usually treated with total or extended colpohysterectomy combined with pelvic lymphadenectomy, often leading to favorable outcome (4). However, this surgical approach is frequently associated with urinary tract complications, with reported incidence ranging from 12% to 85% (5). While each of these conditions can independently lead to urinary tract symptoms, their coexistence is rare and requires tailored management / presents unique management challenges.

In this article, we report the case of a patient diagnosed with both MS and cervical cancer and we highlight clinical impact of this association on lower urinary tract function.

2. Materiel and methods

Clinical case of a young patient who has been receiving care in the Physical and Rehabilitation Medicine Department at the University Hospital Ibn Sina of Rabat, Morocco, for the assessment and management of her urinary tract symptoms.

3. Case study

A 30-year-old single woman has been under neurological care since 2018 for aggressive multiple sclerosis treated with Rituximab. After four years of disease progression and due to her immunodeficiency, she was diagnosed with early-stage cervical cancer. This was surgically managed in November 2022 with a total hysterectomy extended to the parametrium, followed by radiotherapy.

She experiences spontaneous urination and perceives the urge to void, but has difficulty initiating urination / struggles to start urinating, often needing to push with her abdomen. Even after she manages to urinate, she feels incomplete bladder emptying.

To manage her urinary tract issues, a thorough assessment was conducted:

- **Frequency-volume chart**: Maintained over three consecutive days, recording timing, amount, and frequency of her fluid intake and urination. Analysis showed normal fluid intake (2-2.5 liter), urination volumes between 100 and 300 ml at regular intervals, and no reported leakage.
- **Vesicorenal ultrasound**: Showed mild bilateral ureterohydronephrosis, no evident endoluminal obstruction, and two bilateral renal cortical cysts were found, without signs of malignancy.
- **Biological tests**: Cytobacteriological examination of urine and renal function tests were normal.
- **Urodynamic assessment**:
 - **Flow measurement**: Conducted in sitting position with normal voiding desire. The patient urinated with difficulty, voiding 450 ml. Post-void catheterization revealed a residual volume of 550 ml. (Annex 1)
 - **Pressure flow study**: Performed in a gynecological position with a filling rate of 30ml/min. First sensation occurred at 400 ml, with a normal sensation occurring at 453 ml. The detrusor was stable and showed normal compliance. No leakage was observed. Cystometric capacity was 497 ml.

During voiding, there was no detrusor contraction, and the patient was unable to initiate micturition despite abdominal thrusts, (Annex 2)

- **Profilometry**: Baseline urethral pressure was 25 cmH₂O, maximum urethral pressure was 110 cmH₂O, closure pressure was 80 cmH₂, and the functional length of the profile was 71 mm. **Annex 3**

Urodynamic testing indicated bladder hyposensitivity with detrusor hypocontractility.

In total, The patient was a 30-year-old woman being treated for MS and cervical cancer, which had been operated on and irradiated, who presented with dysuria. The tests indicated bladder hyposensitivity and detrusor hypocontractility with early repercussions on the upper urinary tract. Medical treatment with anticholinergics was indicated, along with training in intermittent catheterization.

4. Discussion

4.1. Neuro-uological consequences of total colpohysterectomy for cervical cancer treatment

The pathophysiology of lower urinary tract dysfunction (LUTD) following total colpohysterectomy is multifactorial, involving both neurovascular compromise of the vesico-urethral apparatus and structural injury to the pelvic floor support system. Detailed cadaveric dissection studies have elucidated the anatomical course of sympathetic and parasympathetic fibers within the lesser pelvis, as well as their close relationship to the tissues excised during radical hysterectomy (6).

The mechanisms, severity, and anatomical level of neural injury vary between individuals. Sympathetic fibers arising from the superior hypogastric plexus are at risk of transection or traction injury at the pelvic brim, proximal to the ureter, particularly during the lymphadenectomy stage. The inferior hypogastric plexus—a complex network conveying both sympathetic and parasympathetic fibers—is vulnerable to injury at the level of the cardinal ligament and/or the vesicouterine ligament (7).

The prognosis of these injuries depends on the type and extent of neural damage. Traction-related neuropraxia during dissection often resolves spontaneously within days. In contrast, axonotmesis with preservation of the epineurium allows for potential regeneration, whereas complete neurotmesis precludes recovery (8).

Sympathetic pathway lesions typically result in reduced bladder compliance, elevated detrusor filling pressures, and inadequate coaptation of the bladder outlet during storage. Parasympathetic pathway disruption may lead to detrusor underactivity or acontractility, while injury to afferent pathways can impair bladder and urethral sensation (9).

4.2. Neuro-uological consequences of brachytherapy for cervical cancer

Ionizing radiation used in brachytherapy exerts its cytotoxic effect via two primary mechanisms: direct induction of DNA double-strand breaks and indirect oxidative damage through radiolysis of water, generating reactive oxygen species. While the therapeutic target is malignant tissue, adjacent pelvic organs—including the bladder and urethra—are at risk of collateral injury.

Radiation-mediated degradation of glycosaminoglycans compromises the urothelial barrier, increasing permeability and exposing the suburothelium to chronic inflammatory stimuli. Acute-phase changes include edema, mucosal inflammation, nociceptive activation, and detrusor overactivity. After a variable latent phase, progressive perivascular fibrosis, ischemia, smooth muscle loss, and collagen infiltration culminate in late radiation sequelae such as radiation cystitis, reduced cystometric capacity, diminished compliance, urethral or ureteral strictures, and sphincter insufficiency with urinary incontinence (10).

Urodynamic assessment (UDA) is not routinely indicated for all post-radiotherapy LUTS, but is recommended for patients with symptoms refractory to conservative measures, prior to anti-incontinence surgery, or when upper urinary tract deterioration is suspected. The most frequently observed patterns include detrusor overactivity, low compliance, and reduced urethral closure pressures. Video-urodynamics—or alternatively, voiding cystourethrography combined with pressure-flow studies—are valuable in detecting vesicoureteral reflux that may mask elevated detrusor pressures during cystometry (11).

4.3. Neuro-uological consequences of multiple sclerosis

Lower urinary tract dysfunction is present in the majority of individuals with multiple sclerosis (MS) and may manifest early in the disease course. Symptoms typically emerge a median of six years after neurological onset, but can occur in up to 10% of patients at presentation and in 80–90% over the disease trajectory (10–13).

LUTS in MS encompass both storage and voiding symptoms. The most prevalent are urinary urgency, increased daytime frequency, and urgency urinary incontinence. Voiding phase dysfunction—manifesting as hesitancy, straining, weak stream, or incomplete emptying—often coexists with storage symptoms. Acute urinary retention occurs in up to 73% of patients at some stage. Sensory disturbances, most commonly bladder hyposensitivity, are reported in approximately 75% of cases (15).

Urodynamic profiles are heterogeneous: detrusor overactivity is most frequent (median prevalence 65%), followed by detrusor underactivity (25%) and reduced compliance (2–10%). Detrusor–sphincter dyssynergia (DSD) is variably

reported (median 35%). Notably, the urodynamic pattern may evolve over time, independent of neurological or symptom stability (10–13).

4.4. Application to the present clinical case

In the present patient, storage phase abnormalities may be attributed to either MS-related suprasacral lesions or iatrogenic injury to pelvic autonomic innervation from radical hysterectomy. The voiding phase dysfunction could similarly arise from MS, post-surgical neurogenic sequelae, or post-radiotherapy fibrotic changes within the bladder outlet or urethra.

5. Conclusion

Bladder and sphincter disorders are highly prevalent in individuals with multiple sclerosis and in women who have undergone surgical treatment for cervical cancer, with or without adjuvant pelvic radiotherapy. These LUTD can involve both the storage and voiding phases, leading to a broad spectrum of symptoms such as urinary urgency, frequency, urgency urinary incontinence, voiding hesitancy, or incomplete bladder emptying. Beyond the considerable impact on daily activities, social participation, and emotional well-being, these symptoms may progress to cause upper urinary tract deterioration if left untreated.

Early identification and comprehensive management of LUTD—integrating targeted pharmacological therapy, pelvic floor rehabilitation, intermittent catheterisation when indicated, and, where appropriate, surgical intervention—are essential to preserve renal function, maintain bladder health, and improve quality of life. Multidisciplinary collaboration between urologists, neurologists, rehabilitation physicians, and pelvic floor therapists is critical to optimise outcomes, particularly in complex cases where neurological, oncological, and iatrogenic factors coexist.

Compliance with ethical standards

Disclosure of conflict of interest

No conflict of interest to be disclosed.

Statement of informed consent

Informed consent was obtained from all individual participants included in the study.

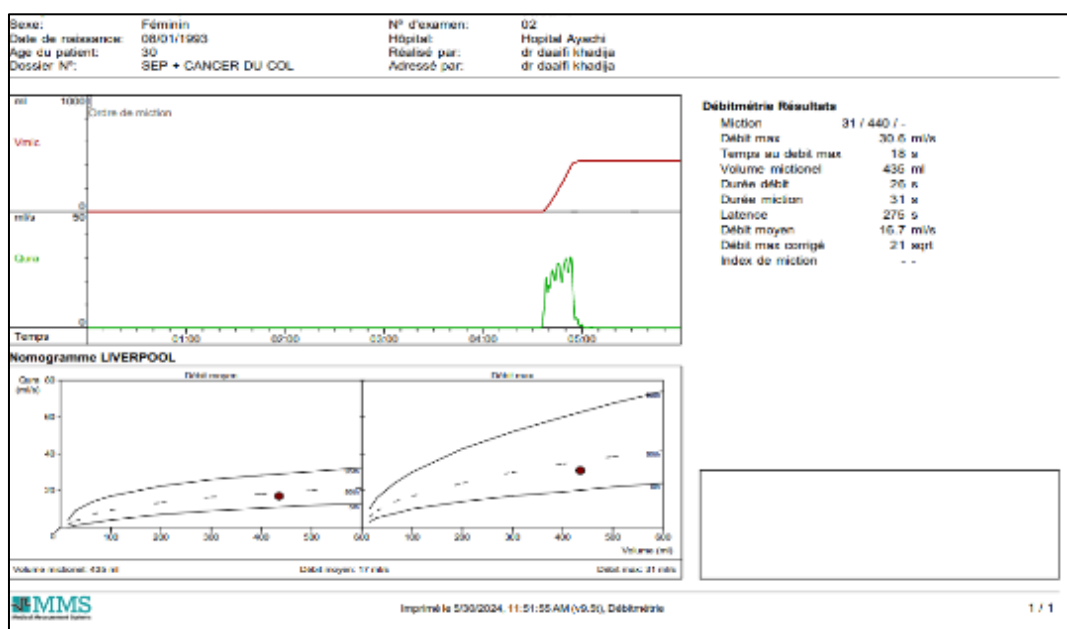
References

- [1] Hinson JL, Boone TBJUC. Urodynamics and multiple sclerosis. 1996;23(3):475-82.
- [2] Sung H, Ferlay J, Siegel RL, Laversanne M, Soerjomataram I, Jemal A, et al. Global cancer statistics 2020: GLOBOCAN estimates of incidence and mortality worldwide for 36 cancers in 185 countries. 2021;71(3):209-49.
- [3] Ferlay J, Colombet M, Soerjomataram I, Mathers C, Parkin DM, Piñeros M, et al. Estimating the global cancer incidence and mortality in 2018: GLOBOCAN sources and methods. 2019;144(8):1941-53.
- [4] Colombo N, Carinelli S, Colombo A, Marini C, Rollo D, Sessa C, et al. Cervical cancer: ESMO Clinical Practice Guidelines for diagnosis, treatment and follow-up. 2012;23:vii27-vii32.
- [5] Vidait A, Mozer P, Chartier-Kastler E, Ruffion AJ. Chapter G – Neuro-urological consequences of gynecological surgery (endometriosis, simple hysterectomy, extended colpohysterectomy), colorectal surgery and pelvic radiotherapy. *Progrès en Urologie*. 2007;17(3):381-4.
- [6] Hinata N, Hieda K, Sasaki H, Murakami G, Abe S, Matsubara A, et al. Topohistology of sympathetic and parasympathetic nerve fibers in branches of the pelvic plexus: an immunohistochemical study using donated elderly cadavers. 2014;47(1):55.
- [7] Mundy A, BJoU. An anatomical explanation for bladder dysfunction following rectal and uterine surgery. 1982;54(5):501-4.
- [8] Hohenfellner R, Fitzpatrick JW, McAninch J. Advanced urologic surgery: John Wiley & Sons; 2008.
- [9] Zullo MA, Mancini N, Angioli R, Muzii L, Panici PB, Crioh. Vesical dysfunctions after radical hysterectomy for cervical cancer: a critical review. 2003;48(3):287-93.

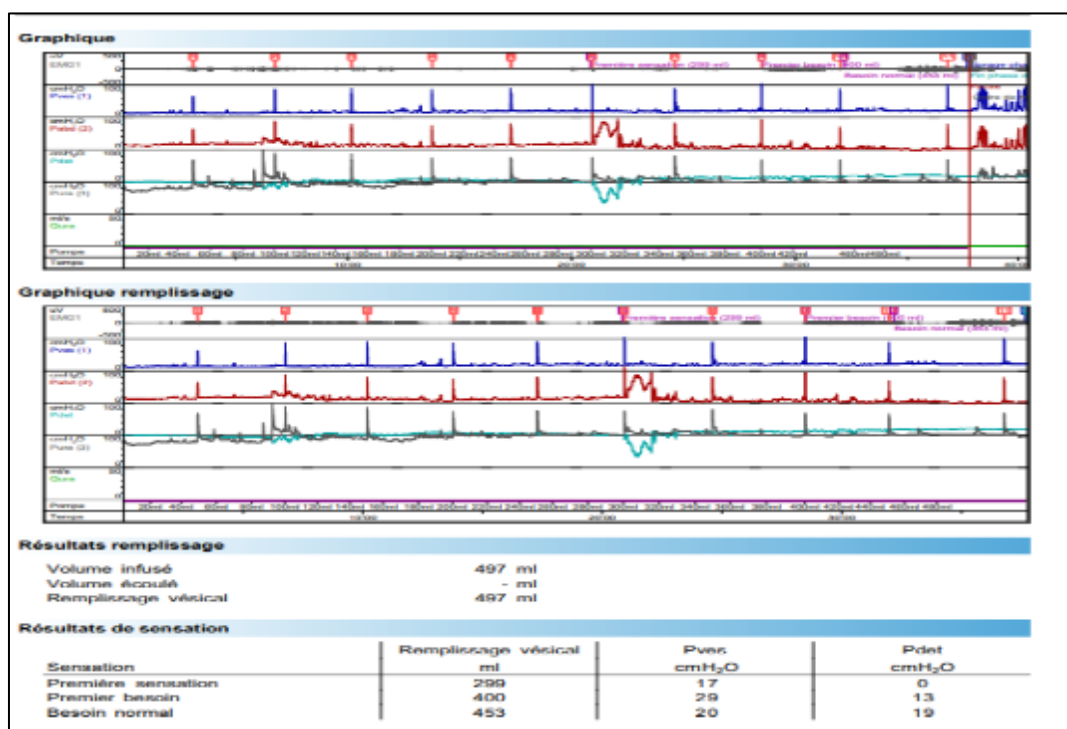- [10] Zwaans BM, Chancellor MB, Lamb LEJU. Modeling and treatment of radiation cystitis. 2016;88:14-21.
- [11] Dubois A, Freton L, Richard C, Haudebert C, Jezequel M, Hascoet J, et al. Genitourinary complications after pelvic radiotherapy: diagnosis and management. Progrès en Urologie. 2023;33(12):563-71.
- [12] De Sèze M, Ruffion A, Denys P, Joseph P-A, Perrouin-Verbe B, Journal IFN-UesgJMS. The neurogenic bladder in multiple sclerosis: review of the literature and proposal of management guidelines. 2007;13(7):915-28.
- [13] Panicker J, Haslam CJBjocn. Lower urinary tract dysfunction in MS: management in the community. 2009;14(11):474-80.
- [14] Chapitre C. Bladder and sphincter disorders and multiple sclerosis. Progrès en Urologie. 2007;17:358-64
- [15] Mayo ME, Chetner MPJU. Lower urinary tract dysfunction in multiple sclerosis. 1992;39(1):67-70.

Annexes

Annex 1: Flow measurement



Annex 2 : Urodynamic test



Annex 3 : Profilometry

